



Original Research Article

Assessment of cheiloscopy pattern in subjects with clinically obvious facial asymmetry

Noor Zaman¹, Tripti Tikku¹, Rohit Khanna¹, Kamna Srivastava¹, Rana Pratap Maurya¹, Sneh Lata Verma^{1,*}¹Dept. of Orthodontics and Dentofacial Orthopedics, Babu Banarasi Das College of Dental Sciences, Lucknow, Uttar Pradesh, India

ARTICLE INFO

Article history:

Received 29-07-2022

Accepted 16-09-2022

Available online 27-10-2022

Keywords:

Lip prints

Cheiloscopy

Facial asymmetry

ABSTRACT

Introduction: Bilateral facial symmetry is rare, however clinically obvious facial asymmetry is of concern. Facial asymmetry results not only in functional, but also esthetic issues. Asymmetries could have pathological, traumatic, functional or developmental causal factors. Lip prints are unique to an individual just like the fingerprints and shows strong hereditary pattern and are useful in forensic science for identification in mass disaster, sex determination and criminal cases etc. Though facial asymmetry is generally evaluated using facial photograph or PA ceph but it was decided to see if there is variation in cheiloscopy pattern in subjects with facial asymmetry. Considering this, it was decided to compare cheiloscopy pattern between subjects with clinically obvious facial asymmetry to normal subjects with no clinically obvious facial asymmetry.

Materials and Methods: Cheiloscopy pattern of 30 subjects were equally divided in 2 groups based on clinical examination-GROUP I(normal with no facial asymmetry) GROUP II (subjects with obvious facial asymmetry) and their cheiloscopy pattern was recorded using photo paper and lipstick. Groove pattern of lip print was assessed as per Tsuchihashi classification-Type I-Complete vertical grooves, Type I'-partial vertical grooves, Type II-forked grooves, Type III-intersected grooves, Type IV-reticular, Type V-undetermined. The assessment was done in 3 zones each (C-centre, R-right, L-left). Adequate statistical comparison were made.

Observation and Results: For right zone, Type I' was most common, both for Group I (40%) and Group II (46.7%). In centre zone, Type I was most common (46.7%) followed by Type II for group I, Type II was most common (40%) followed by Type I(33.3%)for Group II. On left side, Type I and I' are most common(26%) followed by Type II(20%) for Group I and Type I' (46.6%) is most common followed by Type I and Type II for Group II. There was no statistical significant difference between the type of lip pattern for two groups in each zone (C,R,L).

Conclusion: Within the limitation of the study done on smaller sample size it can be stated that cheiloscopy pattern did not show variation with facial asymmetry.

This is an Open Access (OA) journal, and articles are distributed under the terms of the [Creative Commons Attribution-NonCommercial-ShareAlike 4.0 License](https://creativecommons.org/licenses/by-nc-sa/4.0/), which allows others to remix, tweak, and build upon the work non-commercially, as long as appropriate credit is given and the new creations are licensed under the identical terms.

For reprints contact: reprint@ipinnovative.com

1. Introduction

Bilaterally symmetrical development takes place in many parts of the body which means that the right and left

side should have been mirror images. However bilateral symmetry is rarely present. Mild degree of asymmetry is called relative symmetry or subclinical asymmetry.¹ Obvious facial asymmetry is noticeable and is associated with functional issues as well as esthetics. It can negatively affect personality and confidence of an individual. Chia et

* Corresponding author.

E-mail address: drsnehlatagyan@gmail.com (S. L. Verma).

al² suggested that asymmetries could have pathological, traumatic, functional or developmental causal factors. Haraguchi et al³ claimed that the etiology of facial asymmetry can be grouped into hereditary factors of prenatal origin and acquired factors of postnatal origin. Conversely, Cheong and Lo⁴ reported that the causes of facial asymmetry can be grouped into three main categories: (I) congenital, of prenatal origin; (II) acquired, resulting from injury or disease; and (III) developmental, arising during development and of unknown etiology. The lip prints are unique to an individual just like the fingerprints and shows strong hereditary pattern.⁵ It also has been proved that lip prints recover after undergoing alterations such as minor trauma, inflammation and herpes and that the disposition and form of furrows does not vary with environmental factors. The study of lip prints is referred as Cheiloscopy. Lip prints consists of normal lines and fissures in the forms of wrinkles and grooves present in the zone of transition of human lip between the inner labial mucosa and outer skin.⁶ Lip groove pattern are established during 6th week of intrauterine life. The basis of studying the relationship between lip print pattern and various dental anomalies is due to the development of teeth and associated structures, which coincides with the development of epidermal ridges during the 6th -13th week of intrauterine life.⁷ Though facial asymmetry is generally evaluated using facial photograph or PA ceph but it was decided to see if there is variation in chieloscopic pattern in subjects with facial asymmetry. Considering this, it was decided to compare cheiloscopy pattern between subjects with clinically obvious facial asymmetry to normal subjects with no clinically obvious facial asymmetry.

2. Materials and Methods

Sample: Cheiloscopy pattern of 30 subjects were equally divided in 2 groups based on clinical examination-GROUP I(normal with no facial asymmetry) GROUP II (subjects with obvious facial asymmetry).

2.1. Inclusion criteria

1. Patients within age range of 18-25 years.
2. Patients with normal lip morphology.
3. Patients were willing to participate in the study.

2.2. Exclusion criteria

1. Patients who have undergone orthodontic treatment, Orthopaedic. / myofunctional therapy or Orthognathic surgery previously.
2. Patients having any type of mechanical or chemical injury.
3. Individual with known hypersensitivity to lipsticks.

2.3. Materials

2.3.1. For recording lip print

1. Chambor matte riot Tuscany red 202 lipstick.
2. Lip brush.
3. Photo (glossy paper).
4. Sellotape.

2.3.2. For analyzing the lip print pattern

1. Magnifying glass.

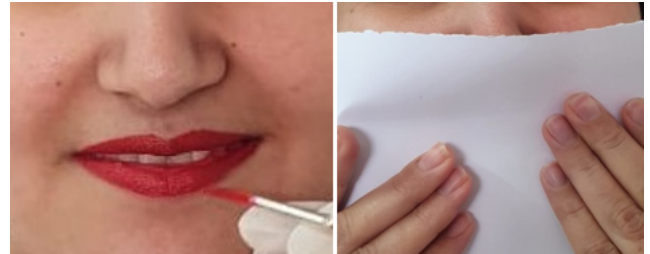


Fig. 1: Methods to record lip print.



Fig. 2: Analyzing lip print pattern.

2.4. Method

1. The participants were asked to sit in relaxed position on a dental chair
2. The lips of the participants were cleaned with the help of wet cotton
3. A portion of red-colored lipstick was cut with the help of Bard-Parker (No. 15) knife to avoid cross contamination and was put into the dappen dish.
4. It was applied on the lips with the help of lip brush
5. The participants were asked to rub both the lips together to spread the lipstick
6. The photo paper strip was placed over the lips, and lip impression was made by pressing the photo paper

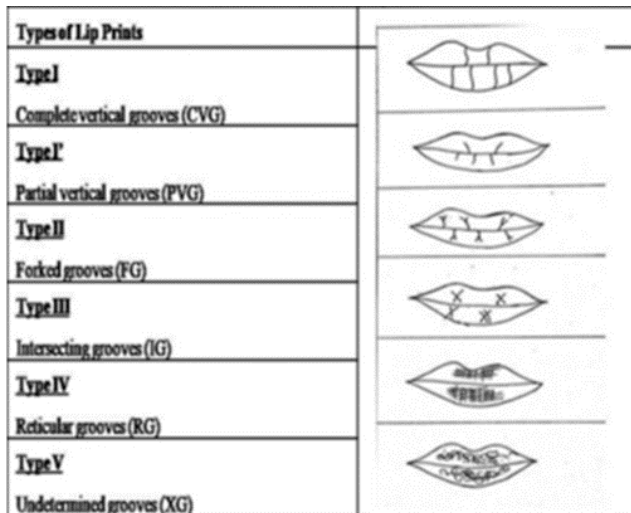


Fig. 3: Different types of lip print pattern observed in the study.

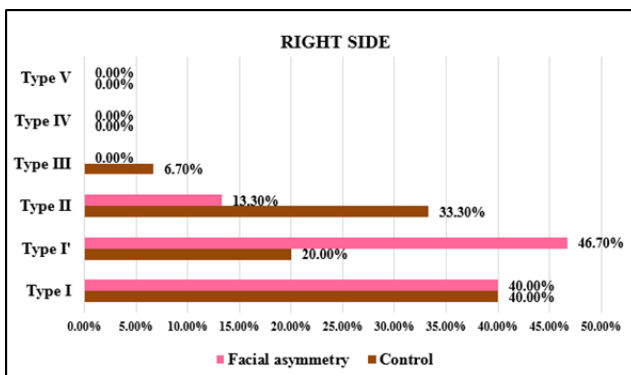


Fig. 4: Bar diagram for cheiloscopy pattern of Group I and Group II of right side.

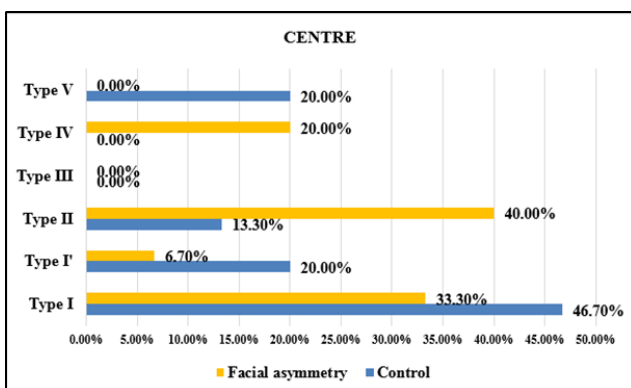


Fig. 5: Bar diagram for cheiloscopy pattern of Group I and Group II of centre.

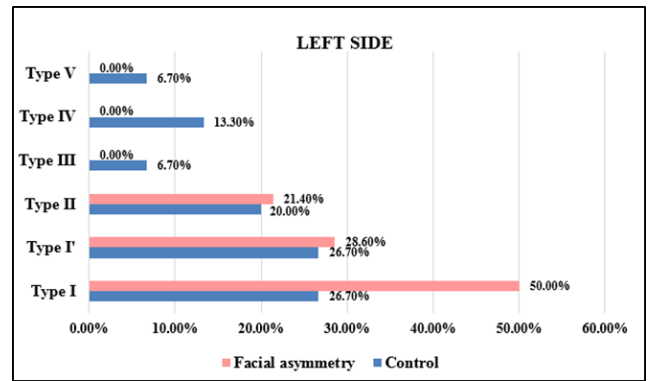


Fig. 6: Bar diagram for cheiloscopy pattern of two group of left side.

strip first at the center of the lips followed by uniformly pressing it toward corner of the lips.

The lip impressions were then visualized with the use of a magnifying lens and was assessed as per Tsuschihashi classification for each sample in 3 zones each (C-centre, R-right, L-left).

1. Type I – Complete vertical groove (CVG)
2. Type I' – Partial vertical groove (PVG)
3. Type II – Forked groove (FG)
4. Type III – Intersecting groove (IG)
5. Type IV – Reticular groove (RG)
6. Type V – Undetermined groove (XG).

3. Discussion

Among the different forensic techniques prevailing in the modern day scenario, cheiloscopy holds a prominent place in personal identification and sex determination. Lip groove pattern are established during 6th week of intrauterine life. The basis of studying the relationship between lip print pattern and various dental anomalies is due to the development of teeth and associated structures, which coincides with the development of epidermal ridges during the 6th -13th week of intrauterine life. Several studies have shown correlation between lip prints and dental caries and malocclusion. Aditi et al 2021⁸ observed Type I' PVG was most prevalent in skeletal Class I malocclusion and Class II Division 2 malocclusion, Type III IG was most prevalent in skeletal Class II Division 1 malocclusion, Type I CVG was most prevalent in skeletal Class III malocclusion. Kulkarni N et al, 2012⁹ observed that a combination of I, III; I', III; and II, III types of lip prints were predominant in skeletal class I group of individuals. I, IV and III, IV types of lip print combinations were predominant among skeletal class III group of patients. I, II type of lip print combination was observed to be more predominant among skeletal class II individuals. Jalannavar P, Prasad R, PatiL P, 2018⁶ observed

Table 1: Observation of cheilosopic pattern of right side for Group I and Group II.

		Right						Total	P value
		Type 1	Type 1'	Type 2	Type 3	Type 4	Type 5		
Control	%	6	3	5	1	0	0	15	0.274
		40.0%	20.0%	33.3%	6.7%	0.0%	0.0%	100.0%	
Facial asymmetry	%	6	7	2	0	0	0	15	
		40.0%	46.7%	13.3%	0.0%	0.0%	0.0%	100.0%	
Total	%	12	10	7	1	0	0	30	
		40.0%	33.3%	23.3%	3.3%	0.0%	0.0%	100.0%	

Table 2: Observation of cheilosopic pattern of centre for Group I and Group II.

		Centre					Total	P Value	
		Type 1	Type 1'	Type 2	Type 3	Type 4			Type 5
Control	%	7	3	2	0	0	3	15	0.053
		46.7%	20.0%	13.3%	0.0%	0.0%	20.0%	100.0%	
Facial Asymmetry	%	5	1	6	0	3	0	15	
		33.3%	6.7%	40.0%	0.0%	20.0%	0.0%	100.0%	
Total	%	12	4	8	0	3	3	30	
		40.0%	13.3%	26.7%	0.0%	10.0%	10.0%	100.0%	

Table 3: Observation of cheilosopic pattern of left side for Group I and Group II.

		Left					Total	P Value	
		Type 1	Type 1'	Type 2	Type 3	Type 4			Type 5
Control	%	4	4	3	1	2	1	15	0.442
		26.7%	26.7%	20.0%	6.7%	13.3%	6.7%	100.0%	
Facial asymmetry	%	7	4	3	0	0	0	14	
		50.0%	28.6%	21.4%	0.0%	0.0%	0.0%	100.0%	
Total	%	11	8	6	1	2	1	29	
		37.9%	27.6%	20.7%	3.4%	6.9%	3.4%	100.0%	

prevalence of dental caries was higher among children with branched groove lip patterns and malocclusion among reticular lip patterns. Considering the variation of lip print pattern with malocclusion it was thought that variation might also be observed in subjects with facial asymmetry. Asymmetries could have pathological, traumatic, functional or developmental causal factors. Facial asymmetry of developmental or congenital origin might show alteration in lip pattern. However none of the studies compared obvious facial asymmetry with cheilosopic pattern and hence no direct comparisons could be made. In this study For right zone, Type I' was most common, both for Group I (40%) and Group II (46.7%)(Figure 3). In centre zone, Type I was most common (46.7%) followed by Type II for group I, Type II was most common (40%) followed by Type I(33.3%)for Group II(Figure 4). On left side, Type I and I' are most common(26%) followed by Type II(20%) for Group I and Type I' (46.6%) is most common followed by Type I and Type II for Group II(Figure 5). There was no statistical significant difference between the type of lip pattern for two groups in each zone (C,R,L). Within the limitation of the study done on smaller sample size it can be stated that chieloscopic pattern did not show variation with facial asymmetry. Further studies with larger sample size and including different malocclusion can be conducted.

4. Conclusion

Chieloscopic pattern did not show variation with facial asymmetry. Further study with larger sample size is required.

5. Source of Funding

None.

6. Conflict of Interest

None.

References

1. Facial asymmetry: a current review. *Dent Press J Orthod.* 2015;20(6):110–25. doi:10.1590/2177-6709.20.6.110-125.sar.
2. Chia MS, Naini FB, Gill DS. The aetiology, diagnosis and management of mandibular asymmetry. *Ortho Update.* 2008;1(1):44–52. doi:10.12968/ortu.2008.1.2.44.
3. Haraguchi S, Iguchi Y, Takada K. Asymmetry of the face in orthodontic patients. *Angle Orthod.* 2008;78(3):421–6.
4. Cheong YW, Lo LJ. Facial asymmetry: etiology, evaluation, and management. *Chang Gung Med J.* 2011;34(4):341–51.
5. Kaushal B, Mittal S, Aggarwal I. Association of Lip Print Patterns with Saggital Malocclusions in District Solan Population. *Int J Res Health*

- Allied Sci.* 2018;4(1):75–81.
6. Jalannavar P, Prasad R, Patil P. Secret behind the lips: Cheiloscopy and its relation to dental caries and malocclusion. *IJSR.* 2018;7(8):28–30.
 7. Shetty SS, Li GS, Babji NA, Yusof LS, Yang NN, Jun TD, et al. Correlative study on lip prints, fingerprints, and mandibular intercanine distance for gender determination. *J Forensic Dent Sci.* 2018;20(3):143–50. doi:10.4103/jfo.jfds_22_16.
 8. Aditi S, Tikku T, Khanna R, Maurya RP, Verma SL, Srivastava K. Association of lip prints in different skeletal malocclusions. *Int J Orthod Rehabil.* 2019;10(4):156–60. doi:10.4103/ijor.ijor_31_19.
 9. Kulkarni N, Vasudevan SD, Shah R, Rao P, Balappanavar AY. Cheiloscopy: A new role as a marker of sagittal jaw relation. *J forensic Dent Sci.* 2012;4(1):6–12.

Author biography

Noor Zaman, Post Graduate Student

Tripti Tikku, Professor

Rohit Khanna, Professor and Head

Kamna Srivastava, Reader

Rana Pratap Maurya, Reader

Sneh Lata Verma, Reader

Cite this article: Zaman N, Tikku T, Khanna R, Srivastava K, Maurya RP, Verma SL. Assessment of cheiloscopy pattern in subjects with clinically obvious facial asymmetry. *IP Indian J Orthod Dentofacial Res* 2022;8(3):146-150.