



## Case Report

# RME as an aid to relieve excess crowding: Illustration with a case report

Fatima Alam<sup>1,\*</sup>, Adeel Ahmed Bajjad<sup>1</sup>, Arun Kumar Chauhan<sup>1</sup>

<sup>1</sup>Dept. of Orthodontics & Dentofacial Orthopaedics, Kothiwal Dental College & Research Centre, Moradabad, Uttar Pradesh, India



### ARTICLE INFO

#### Article history:

Received 08-09-2021

Accepted 16-09-2021

Available online 22-10-2021

#### Keywords:

RME

Anterior crowding

Nonextraction

Active retainer

### ABSTRACT

This case report describes the orthodontic treatment of a 13-year-old female patient who was diagnosed as Angle's Class I malocclusion, posterior crossbite along with severe space deficiency. The space deficiency of 10 mm was noted in maxillary arch with complete block out of left central incisor, and posterior crossbite. The treatment plan presented non-extraction with rapid maxillary expansion. A bonded hyrax expander was used in a rhythm of 2 turns/day for 3 weeks, stabilized for 3 weeks, later followed by fixed appliance therapy on a 0.022 x 0.028 inch PEA on MBT prescription. The case was treated as non extraction. The treatment resulted in aesthetically pleasing facial profile with a normal overjet and overbite, and functional occlusion.

This is an Open Access (OA) journal, and articles are distributed under the terms of the [Creative Commons Attribution-NonCommercial-ShareAlike 4.0 License](https://creativecommons.org/licenses/by-nc-sa/4.0/), which allows others to remix, tweak, and build upon the work non-commercially, as long as appropriate credit is given and the new creations are licensed under the identical terms.

For reprints contact: [reprint@ipinnovative.com](mailto:reprint@ipinnovative.com)

## 1. Introduction

Rapid maxillary expansion (RME) is a common procedure which has been used for more than a century to correct maxillary transverse deficiency. The earliest common cited report is that of E.C. Angell published in Dental Cosmos in 1860.<sup>1</sup> Adkins et al. have demonstrated that expansion of 1 mm in trans-palatal width increases arch perimeter by 0.7mm.<sup>2</sup> In 2003, McNamara et al. evaluated the short- and long-term changes in dental arch dimensions in patients treated with RME followed by fixed edgewise appliances; they concluded that a net gain of 6 mm was achieved in the maxillary arch perimeters as compared to the untreated controls.<sup>3</sup> As a result, RME is a viable option to correct transverse discrepancies and create additional space in the dental arch, which offers the possibility of non-extraction treatment selection. Clinical indications for rapid maxillary expansion are a lateral crossbite or a constricted maxillary arch, wide buccal corridors- the negative space, etc. In addition, the increase in arch length allows for reducing

the lack of space for crowded teeth.<sup>4</sup> Arch expansion not only prevents the detrimental effect of improperly planned extractions on facial aesthetics but also facilitates the complete development of the dental arch, thus allowing the teeth to be orthodontically repositioned within the enhanced alveolar processes and eliminating the need for the removal of permanent teeth in many cases.<sup>5</sup>

This paper presents a case of a 13-year-old female patient who was treated with Rapid Maxillary Expansion using a bonded hyrax appliance, to correct posterior crossbite and to gain arch length to relieve severe crowding, the case was thus treated successfully as non-extraction.

## 2. Case Report

A 13-year-old female patient reported to the department with the chief complain of irregularly placed teeth in the upper dentition.

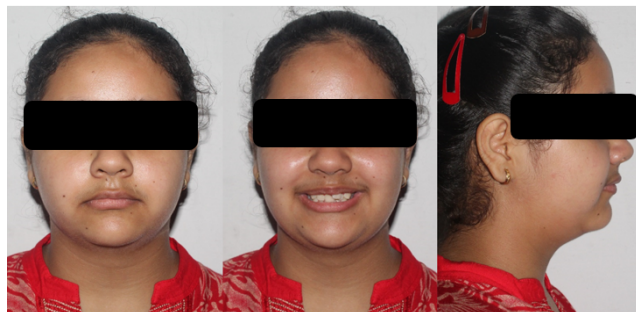### 2.1. Diagnosis and etiology

Extra oral findings (Figure 1) revealed bilaterally symmetrical face, lips competent at rest, profile photograph

\*Corresponding author.

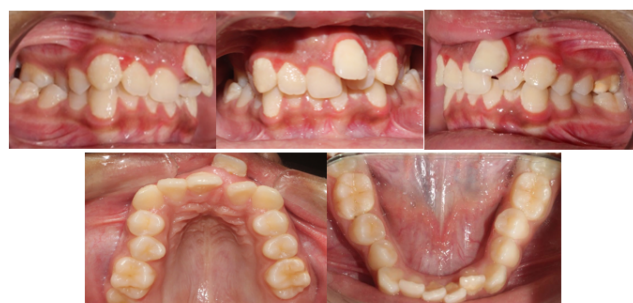E-mail address: [dr.alam\\_fatima@icloud.com](mailto:dr.alam_fatima@icloud.com) (F. Alam).

reveals convex profile with acute nasolabial angle and average mentolabial sulcus, average mandibular plane. On smiling there is complete incisor exposure with a non-consonant smile arc.



**Fig. 1:**

Intra-oral findings (Figure 2) reveals class II molar relation and canine relation bilaterally, presence of posterior cross bite, maxillary arch is U-shaped with dentoalveolar distortion, blocked out left central incisor and presence of crowding, a leftward midline discrepancy of 4 mm, mandibular arch is also U-shaped with presence of crowding. Arch perimeter indicated arch length deficiency by 9 mm and Carey's analysis revealed arch length deficiency by 7 mm. Bolton's analysis revealed overall maxillary excess by 1.3 mm. Pont's analysis indicated need for expansion in the upper arch.

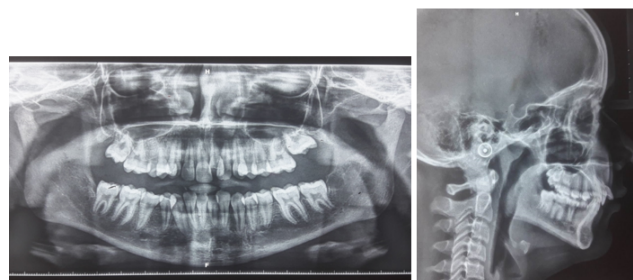


**Fig. 2:**

The OPG (Figure 3) of the patient reveals all the permanent teeth have erupted in the oral cavity except for the upper 2<sup>nd</sup> molars, the 3<sup>rd</sup> molars are yet to be developed. The lateral cephalogram (Figure 3) of the patient reveals patient being in CVMI stage 4, class I skeletal pattern, with average mandibular plane, the maxillary incisors were proclined and protruded.

## 2.2. Treatment objectives

The treatment objectives were to (i) address the severe arch-length deficiency in maxillary and mandibular arch, (ii) attain adequate space to alleviate anterior crowding



**Fig. 3:**

**Table 1: Cephalometric readings**

Values and Measures	Actual	Pre-t/t
SNA Angle	82°	84°
SNB Angle	80°	81°
ANB Angle	20	3°
N Point A(mm)	0±2mm	1 mm
N Pog (mm)	0 to -4mm	-6 mm
GoGn to SN (Angle)	32°	29°
Angle of inclination	85°	86°
LAFH (mm)		62 mm
Max Length (mm)		78 mm
Mand Length (mm)		95mm
Y axis (Angle)	53-66°	63°
Facial Axis (Angle)	0±3.5	7°
Sum of Post Angle	396 ± 6°	389°
U1 to NA (Angle)	22°	32°
U1 to NA (mm)	4mm	8 mm
U1 to SN (Angle)	102°	122°
L1 to NB (Angle)	25°	25°
L1 to NB (mm)	4mm	3 mm
L1 to A-Pog (mm)	1 to 2mm	2 mm
L1 to Md Plane	90°	93°
S Line to upper lip	-2mm	3 mm
S Line to lower lip	0mm	0mm

and facilitate alignment of maxillary left central incisor, (iii) level and align upper and lower dentition, (iv) obtain Class I molar relation and class I canine relation bilaterally, (v) correction of crossbite, (vi) relieve crowding in upper and lower arches, (vi) obtain optimal overjet and overbite, (vii) obtain a consonant smile arc, (viii) obtain functional occlusion, optimal facial esthetics and pleasing facial profile.

## 2.3. Treatment plan

Possible treatment options including premolar extraction and non-extraction therapy were considered. Since the extraction of all 4 first premolars would have resulted in a concave and exceedingly flat profile, therefore, extraction therapy was not considered as a viable treatment option. Considering the relatively young age and the influence of growth on dentofacial esthetics, non-extraction modality

involving carefully monitored “RME” with a bonded hyrax appliance was deemed a better treatment option for alleviation of maxillary crowding, and improvement in facial profile.

Treatment Progress: Maxillary expansion was initiated with the use of a tooth-borne Hyrax assembly (Figure 4). The patient was instructed to activate the appliance once a day for 21 days, as the semi-RME protocol was followed, which involved activation of the screw by two-quarter turns per day for the first week, followed by one-quarter turn per day every other day for the next 2 weeks. Once sufficient expansion had been achieved with the buccal crest of the upper posterior teeth just approximating the lingual crest of the buccal cusps of the lower permanent molars, the screw was locked, and the expander served as a stabilizer for the next 3 months.

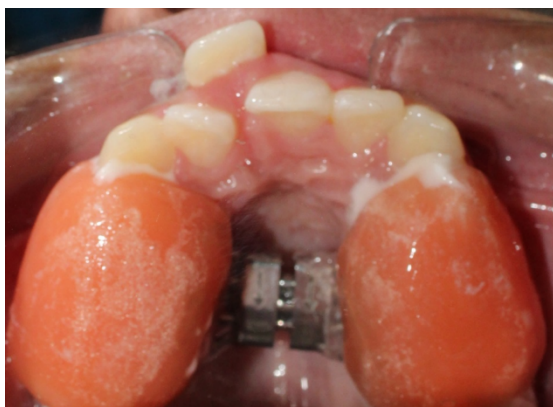

Fig. 4:

Post stabilization, 0.022” × 0.028” slot pre-adjusted edgewise brackets (MBT prescription) were bonded in the upper arch except for left central incisor (Figure 5). Alignment was performed, post sufficient alignment a compressed nickel-titanium open-coil spring on a 0.016” × 0.022” stainless steel (SS) wire was used to open the needed space for left central incisor (Figure 6). The central incisor was later bonded with a MBT bracket on the labial surface to permit alignment of the crown (Figure 7).

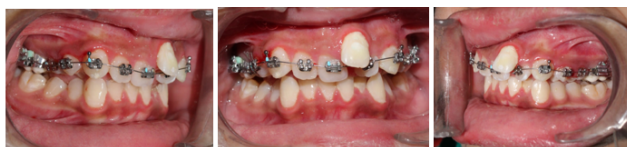

Fig. 5:

The lower arch was bonded with 0.022” × 0.028” slot pre-adjusted edgewise brackets (MBT prescription). A normal progression of continuous archwires was used to level, align, and coordinate the arches (Figure 8). Settling was performed with double intra oral elastics to obtain

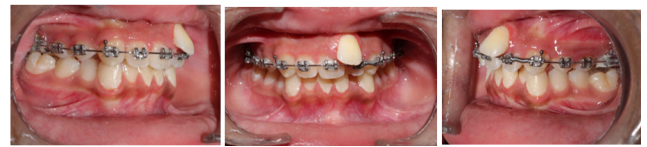

Fig. 6:

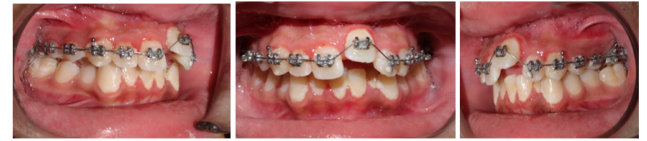

Fig. 7:

intercuspsation (Figure 9).

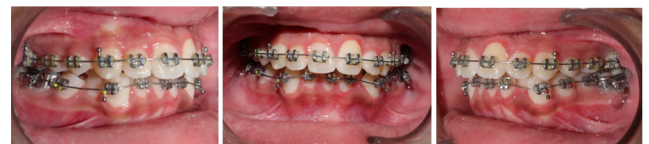

Fig. 8:

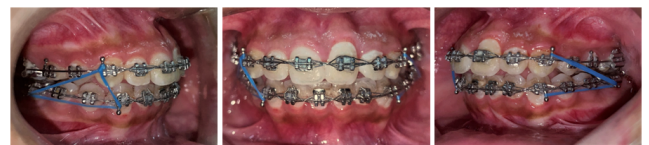

Fig. 9:

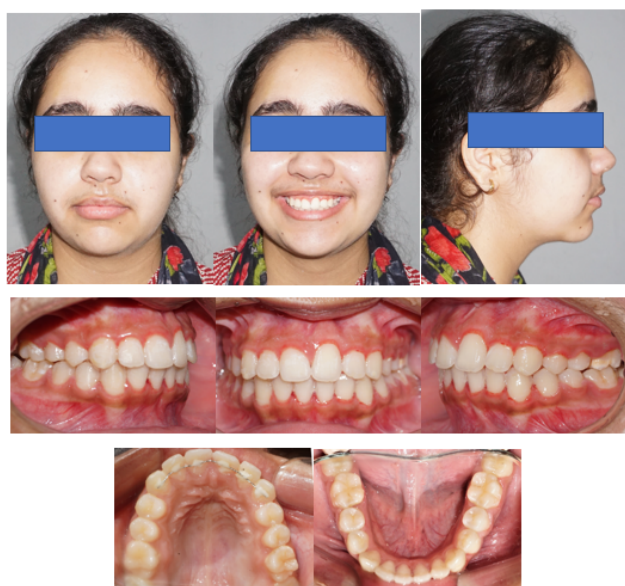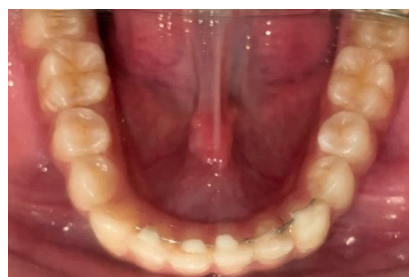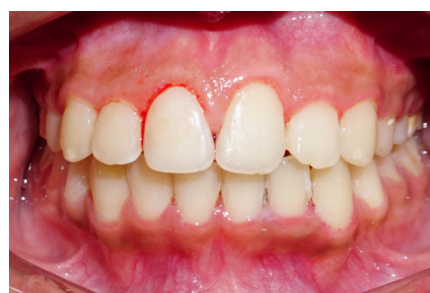### 3. Treatment Results

After a total 24 months of treatment, satisfactory dental alignment and acceptable overjet and overbite were achieved (Figure 10). Upon debonding it was observed that the lower left lateral incisor was slightly rotated in the mesial direction, hence a 0.016 inch NiTi active retainer (Figure 11) was bonded in the lower arch to facilitate its correction and a fixed retainer were placed in maxillary arch to maintain tooth positions. Also, gingivectomy was performed in relation to 11 (Figure 12).

The final radiographs indicated root parallelism, proper root alignment, and no obvious root resorption (Figure 13). Post treatment cephalometric readings (Table 2) indicated improvement in incisor angulations, and positions of upper and lower lips in relation to S line. Superimposition of cephalometric tracings (Figure 14) indicated that the sagittal relationship of basal bone was generally maintained, with slightly downward and backward rotation of the mandibular basal bone, which led to an increase in the mandibular plane angle by 1°.

**Table 2:** Post-treatment cephalometric readings

Values and Measures	Actual	Pre-t/t	Post-t/t
SNA Angle	82 <sup>0</sup>	84 <sup>0</sup>	84°
SNB Angle	80 <sup>0</sup>	81 <sup>0</sup>	82°
ANB Angle	20	3 <sup>0</sup>	2°
N Point A(mm)	0±2mm	1 mm	0 mm
N Pog (mm)	0 to -4mm	-6 mm	-5 mm
GoGn to SN (Angle)	32 <sup>0</sup>	29 <sup>0</sup>	30°
Angle of inclination	85 <sup>0</sup>	86 <sup>0</sup>	88
LAFH (mm)		62 mm	64 mm
Max Length (mm)		78 mm	79 mm
Mand Length (mm)		95mm	97 mm
Y axis (Angle)	53-66 <sup>0</sup>	63 <sup>0</sup>	60°
Facial Axis (Angle)	0±3.5	7 <sup>0</sup>	4°
Sum of Post Angle	396 ± 6 <sup>0</sup>	389 <sup>0</sup>	393°
U1 to NA (Angle)	22°	32°	25°
U1 to NA (mm)	4mm	8 mm	4 mm
U1 to SN (Angle)	102°	122°	110°
L1 to NB (Angle)	25°	25°	28°
L1 to NB (mm)	4mm	3 mm	6 mm
L1 to A-Pog (mm)	1 to 2mm	2 mm	4 mm
L1 to Md Plane	90°	93°	97°
S Line to upper lip	-2mm	3 mm	-1 mm
S Line to lower lip	0mm	0mm	-1 mm

**Fig. 10:****Fig. 11:****Fig. 12:**

#### 4. Discussion

In 1990, Adkins et al. have demonstrated that every millimeter of trans-palatal width increase in the premolar region produces a 0.7 mm increase in available maxillary arch perimeter.<sup>2</sup> In 2003, McNamara et al. evaluated the long-term changes in dental arch dimensions in patients treated with RME followed by fixed edgewise appliances.

The subjects were about 12 years old at the beginning, and their average long-term observation period was about 8 years. They concluded that a net gain of 6 mm was achieved in the maxillary arch perimeters and 4.5 mm in the mandibular arch perimeter as compared to the untreated controls.<sup>3,6</sup> In 2010, Hakan Gurcan Gurel et al. evaluated

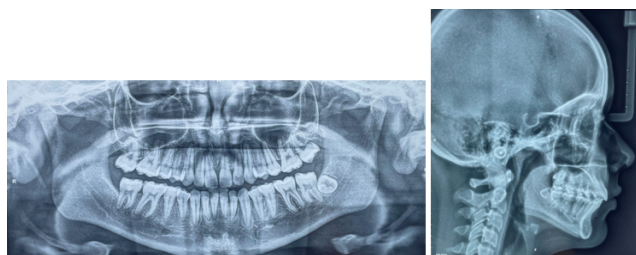

Fig. 13:




Fig. 14:

the long-term changes in maxillary arch widths, overjet and overbite in patients who were treated with RME followed by edgewise appliance. The subjects were about 13 years old at the beginning, and their average long-term observation period was about 7 years. They concluded that the treatment produced absolute increases in maxillary arch widths.<sup>6</sup>

From the above studies, we can assure the treatment efficiency of RME in increasing inter-molar width and arch perimeter. Numerous factors such as soft-tissue profile, health of oral tissues, inclination of the posterior teeth, and individual growth potential, should be taken into consideration when making treatment decision for RME. Arch expansion not only prevents the detrimental effect of improperly planned extractions on facial esthetics but also facilitates the complete development of the dental arch, thus allowing the teeth to be orthodontically repositioned within the enhanced alveolar processes, and eliminating the need for the removal of permanent teeth in many cases.<sup>7</sup> A transpalatal width of 35–39 mm suggests adequate size of bony base to accommodate average-sized permanent teeth.<sup>8</sup> In this case, the patient had a posterior crossbite, a clear indication for expansion therapy, therefore a hyrax expander was used to take advantage of its dental effect. After 3 weeks expansion and a stabilisation period of 3 months, a significant correction of posterior crossbite was observed. The second phase of treatment involving fixed appliance therapy, with the help of open coil spring, gained sufficient space for proper alignment of the teeth resulting in a non extraction treatment in present of excess crowding. Post treatment results clearly justify the need for expansion in this case where proper inclination of posterior teeth was achieved with correction of posterior cross bite, as well as

increase in arch length, and the case successfully completed as a non extraction case.

Upon debond, it was observed that the lower left lateral incisor was slightly tipped in the mesial in direction, hence an active NiTi fixed retainer was placed in the lower arch for its correction. A resilient nickeltitanium (NiTi) archwire is an excellent alternative to stainless steel multi-stranded or plain archwire for use as a bonded lingual retainer or as an active appliance for solving relapse of mandibular anterior crowding without brackets. The technique involves bonding a segment of mandibular NiTi archwire lingually canine to canine to solve relapse of mandibular anterior crowding and to serve as a post-treatment bonded lingual retainer.<sup>9</sup> The NiTi wire, in this case was successful in correcting the position of the lower left lateral incisor in a duration of 2 weeks, when the patient was seen in follow up visit. The NiTi wire was then left in place to serve as a retainer.

## 5. Conclusion

In this case report, a 13-year old female patient who was diagnosed as Angle's Class I malocclusion, presence of posterior cross bite, severe space deficiency was successfully treated as non extraction utilising RME on a bonded hyrax. Although there are extreme chances of ossification of mid palatal suture by this age, still dentoalveolar expansion resulted in positive treatment outcomes. Also, a lingually bonded fixed retainer of 0.016-inch NiTi, which served as an active retainer, was successful in correcting the mesial in rotation on lower left lateral incisor.

## 6. Source of Funding

None.

## 7. Conflict of Interest

None.

## References

1. Timms DJ. The dawn of rapid maxillary expansion. *Angle Orthod.* 1999;69(3):247–50.
2. Adkins MD, Nanda RS, Currier GF. Arch perimeter changes on rapid palatal expansion. *Am J Orthod Dentofac Orthop.* 1990;97:194–9.
3. Mcnamara JA, Baccetti T, Franchi L, Herberger TA. Rapid maxillary expansion followed by fixed appliances: a long-term evaluation of changes in arch dimensions. *Angle Orthod.* 2003;73:344–53.
4. Mutinelli S, Cozzan M. Rapid maxillary expansion in contemporary orthodontic literature. *APOS Trends Orthod.* 2016;6:129–36.
5. McDougall PD, Mcnamara JA, Dierkes JM. Arch width development in class II patients treated with the Fränkel appliance. *Am J Orthod.* 1982;82:10–22.
6. Gurel HG, Memili B, Erakn M, Sukurika Y. Long-term effects of rapid maxillary expansion followed by fixed appliances. *Angle Orthod.* 2010;80:5–9.
7. Sabri R. Treatment of a severe arch-length deficiency with anteroposterior and transverse expansion: Long-term stability. *Am J Orthod Dentofacial Orthop.* 2010;137(3):401–11.

8. Singh H, Kapoor P, Sharma P, Maurya RK, Mittal T, Bhagat D. Treatment of a Severe Tooth Size&#8209;arch Length Discrepancy Using Rapid Maxillary Expansion and Mandibular Incisor Extraction: An Unconventional Combination Approach. *J Indian Orthod Soc.* 2019;53(1):69–76.
9. Liou E, Chen JW, Huang CS. Nickel-titanium mandibular bonded lingual 3-3 retainer: For permanent retention and solving relapse of mandibular anterior crowding. *Am J Orthod Dentofacial Orthop.* 2001;119:443–9.

**Adeel Ahmed Bajjad**, Senior Lecturer

**Arun Kumar Chauhan**, Professor

**Cite this article:** Alam F, Bajjad AA, Chauhan AK. RME as an aid to relieve excess crowding: Illustration with a case report. *IP Indian J Orthod Dentofacial Res* 2021;7(3):255-260.

### **Author biography**

**Fatima Alam**, Private Practitioner